THE SOUL OF DENTISTRY AT IBN SINA UNIVERSITY

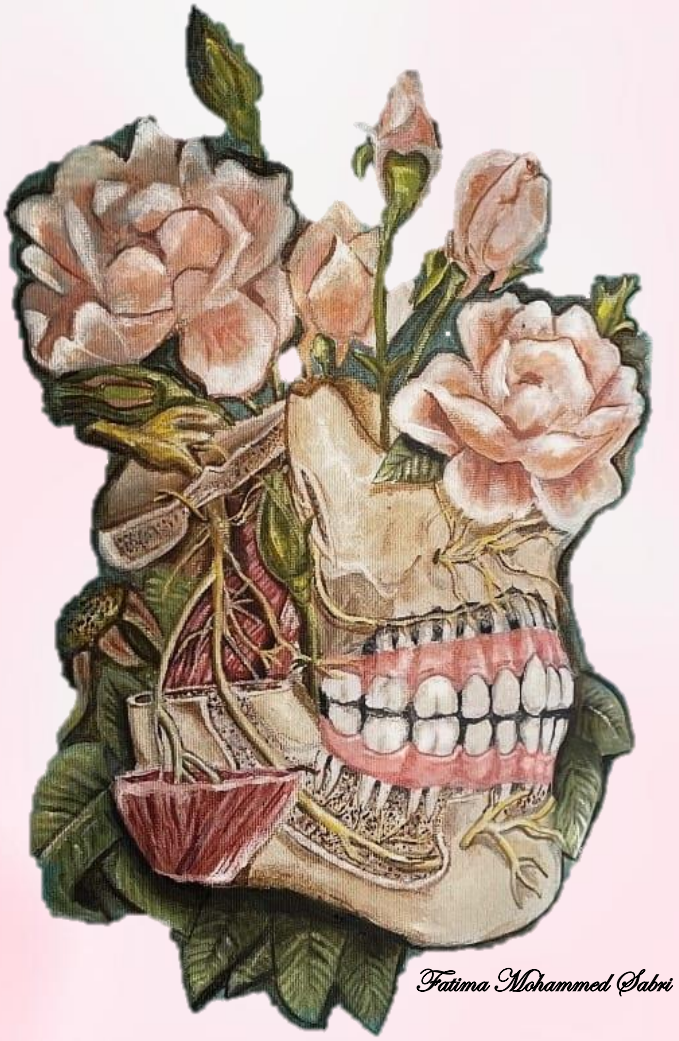

Fatima Mohammed Sabri

Members

Done by:

- **Lec. Zahraa Karkosh (M.Sc. Pros.)**
- **Assist. Lec. Hajer Najah Abdulsaheb (M.Sc. Sys. Programming)**
- **Assist. Lec. Mais Mahdi Almaeeni (M.Sc. Pedo.)**
- **Assist. Lec. Eman Alaa Jaffer (M.Sc. prevention)**
- **Mustafa Qais (B.D.S. Media)**

Supervised by:

Prof. Dr. Dunia W. Sabea

M. Sc. oral surg.

Ph. D. oral patho

Acknowledgements

The members of scientific bulletin extend their thanks to the president of Ibn-Sina University ***Prof. Dr Abbas AL- Sherafy***. The members of scientific bulletin extend their gratitude to ***Asst. Prof. Dr. Widad Allawi Saddam*** for correcting the spelling of the bulletin. Special thanks for ***Asst. Prof. Dr. Raya Rasheed*** and ***Assist. Prof. Dr. Faaz Yaqoob.***

Clinics Patients Counts

❖ The number of patients who had been visited or number of attendance clinics of Ibn-Sina University for medical and Pharmaceutical science:

No.	Clinics	Counts
1.	Oral surgery	950 patients
2.	Prosthodontics	1650 patients
3.	Orthodontics	128 patients
4.	Operative	2230 patients
5.	Oral medicine	405 patients
6.	Periodontology	1655 patients
7.	Pedodontics	586 patients
8.	Prevention	645 patients
Total: 8249 Patients		

Dentistry Dean and Teachers

Table of Contents

1- Students Innovations

❖ Making Training models by new material

By: Hashim Ibrahim/ 5th year student

I've stumbled upon a revolutionary material that promises to reshape the landscape of prosthodontics, surgery, and orthodontics. This innovative substance not only boasts unparalleled ease of use but also comes with the added advantage of being remarkably cost-effective. As I delve into the potential applications of this newfound material, the prospect of enhancing training models for dental procedures becomes increasingly promising. The fusion of accessibility and affordability positions this discovery as a game-changer in the realm of dental sciences, opening doors to more accessible and economical advancements in prosthodontics, surgery, and orthodontics. The material is resin and is used in many fields, including accessories, construction works, and floor finishing, polishing decorative works. Polishing decorative works.

1

It can be used as one of the steps in training students to use partial or complete dentures, as well as to explain Angle's classification

2

In orthodontics, where you can practice various types of clasps and brackets

3

In dental surgery, we can learn about dental anesthesia methods using anatomical landmarks, as well as dental implant procedures.

2- Students Innovations

❖ Repurposing Old Devices for Innovation in Dentistry

By: Tariq Mohammed Abdulmalik/ 5th stage Dentistry student

Reusing and recycling items have been hobby of mine since my teenage years. I used to reconstruct, build, and repurpose things, both for fun and practical purposes. In this article, I'll demonstrate how I repurposed an old PlayStation controller to create a highly useful tool that greatly benefited my prosthodontics clinic.

What is the tool?

The tool is simply a small vibrating platform that helps to eradicate and eliminate air bubbles that may form in the cast if it wasn't adequately vibrated during the pouring process with stone.

Why did I make this tool?

The root cause originated last year, during the 4th stage of my work. It was my first impression for the prosthodontics clinic, and I wasn't aware of all the potential problems that could arise. When I poured the impression, there was no regular impression vibrator available in the clinic. I attempted to vibrate it manually with my hands and by tapping it on the bench, but unfortunately, this method wasn't effective enough. A significant air bubble formed in the abutment tooth, forcing me to redo the impression. This issue persisted, with multiple air bubbles forming in subsequent casts despite prolonged tapping on the bench.

It became clear that hand vibrating was insufficient to completely eliminate air bubbles. Since then, I've been contemplating a tool to address this issue, as it's not only frustrating but also detrimental to the quality of the casts. Hand tapping is exhausting and often ineffective. That's when the idea for this tool struck me.

How did I make the tool?

I salvaged four vibrating motors from two old gaming controllers. These motors operate by attaching a weight to one side, generating a jerking and vibrating motion when activated.

I repurposed the box of a dental hand piece as a platform for the motors. This platform is essential as it provides a stable surface to place the impression while pouring and allows for the air bubbles to rise up.

I utilized a standard USB cable (typically used for phone charging) to power the motors. I removed the portion that connects to the phone.

I used an on/off switch to turn the vibrator on and off.

For energy supply, I used a 6-volt power bank (portable phone charger).

After assembling all the components, here it is: a compact, useful, and convenient vibrator. It's easy to use, portable, and doesn't require a massive energy source. Simply use a normal phone charger or a power bank, and you're ready to go.

I gave the vibrator a try, and the results was very satisfactory.

Before using the vibrator

After using the vibrator

The vibrator showed very good results in reducing air bubble formation in the poured cast; you just need to give it some time. Maybe it's not as efficient as the normal dental impression vibrator, but for me as a student, it does the job very effectively.

3- Students Innovations

❖ ATLAS, new generation of dental technology

By: Karar Alaa Mohammed/ 4th Stage

That was the logo created to keep up with developments and facilities in the dentistry world. We aim to make procedures in dental clinics faster and easier for both dentists and patients, with less scribbling and more efficiency.

In this chapter, we will talk about the first device, "Atlas Strong," the alternative to "Engine Strong." So, what is going to be distinct about "Atlas" to make it an alternative to "Engine"?

1- Atlas Strong works on charging batteries, not electric current. Sometimes electricity faults happen everywhere (in dental clinics, prosthodontic labs, phantom labs, etc.), so we have to solve this problem and save our time.

VS



2- Atlas Strong involves less scribbling with its components compared to Engine Strong. Atlas Strong has a regular shape with fewer electricity wires, unlike Engine Strong, which makes the working area more complicated. Many studies deal with the effects of a random working area on staff. This leads to negative results due to distracted focus and missing the target.



VS

3- Atlas Strong has a "hand switch," the alternative to the "foot switch" in Engine Strong. The most important component in this device makes work more easily accomplished with it. The components of Atlas Strong are as follows:

- **6 Charging Battery**

  In each cage, there are 3 batteries, with 2 of them connected in parallel and the remaining one connected in series combination. Each battery has 3.7 V and 3800 mAh, which makes it work strongly for a long time.

Students Innovations

- Engine motor: the same as in Engine Strong but in the future will be replaced with another one depending on the engine's torque and its size.

- **electronic board charging**: It connect with switch that separate it from the main board



- The main board has a key to change the voltage; it has the ability to hold 12V to 16V and regulates the outgoing current amperage.



- The holder base has a pair of adhesive tapes; it can be worn on the thigh, hand, or even placed on the table.

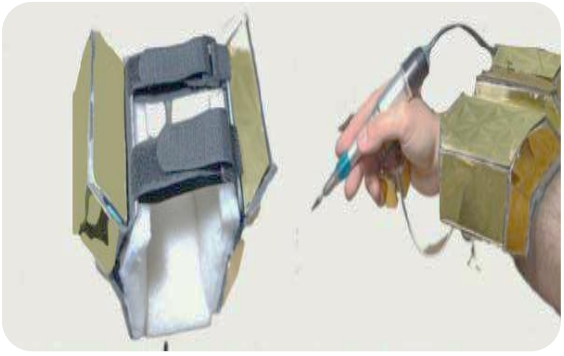

- **Hand switch:** has a single adhesive tape and a wire that connects to the device. It can be easily used by the last two fingers to hold the engine motor with the rest of the fingers.



The advantages of hand switch idea is:-

- Making the procedures easier and faster.
- Its shape reduces scribbling in the working area.
- Some dentists may complain about the use of the foot switch.
- Many people with physical disabilities have big dreams and capacity for creativity in dentistry, but their foot condition can't help them achieve their dreams. Therefore, this device will make a successful change in the future.

Finally, this is not the last device from Atlas; many generations and changes will occur to Atlas Strong and the rest of the devices that will be produced.



Miscellaneous adopted ideas

How can Artificial intelligence (AI) be used to help dentist?

By: Zainab Jamal (B.D.S)

Artificial Intelligence (AI) is transforming and revolutionizing dentistry, improving diagnostics, and personalized care. AI analyzes dental images for accurate issue detection and processes patient data to create customized treatment plans.

• Predictive analytics enable early intervention to prevent oral health problems. •Appointment scheduling and billing allow dental professionals to focus more on patient care. This relationship between AI and dentistry introduces efficient, precise, and elevating overall oral healthcare. Artificial Intelligence is redefining new-age dentistry (1).

Students Cases under Teacher's Supervision

Fatima Mohammed Sabri

Students Cases under Teacher's Supervision

Supervised by: Lec. Zahraa Karkosh
Ruaa Sabeeh Nsaif (B.D.S)
Student Name: Zahraa Karem Azez / 4th stage

- A 40-year-old patient attended the prosthodontic clinic seeking removable denture construction. After intra-oral examination, the patient was found to have small to moderate-sized mandibular tori on both sides. It had been decided to make relief for both tori to prepare the denture foundation area for receiving the partial denture.

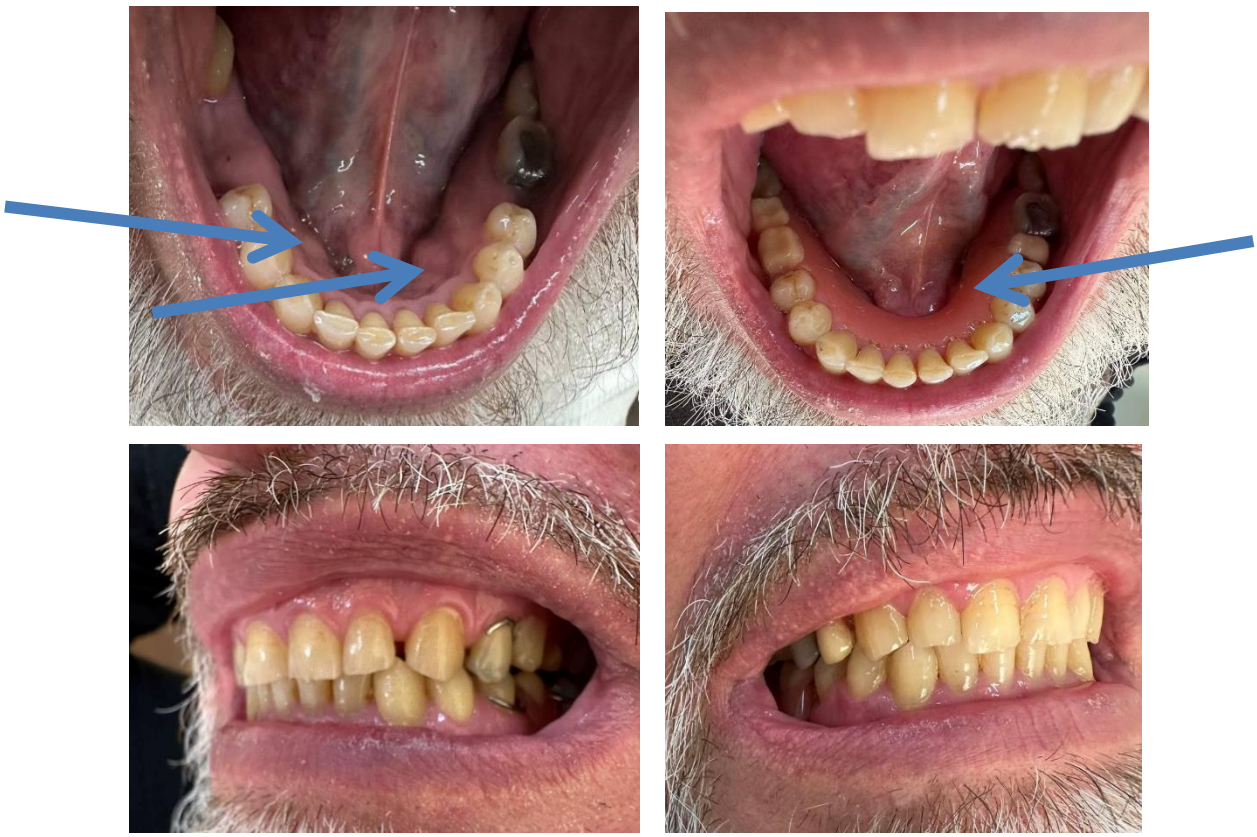

Students Cases under Teacher's Supervision

Supervised By: Lec. Zahraa Karkoosh
Fatima Mohammad sabri (B.D.s)/ Zanaib jamal (B.D.S)
Zahraa Damer (B.D.S)
Student Name: Ameer sadik (student)

❖ This patient refuses to extract his lower canine, as this tooth provides him with psychological and functional confidence. This was the reason for choosing the immediate denture solution. The patient has no systemic disease.

1

2

3

4

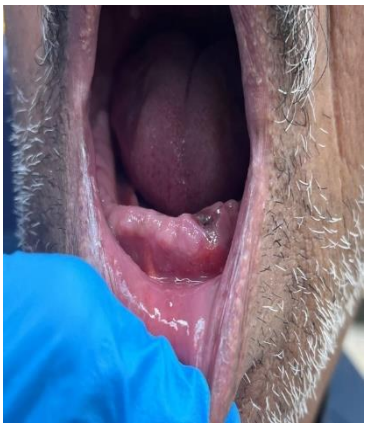

5

Result

Students Cases under Teacher's Supervision

Supervised By: Asst. Lec. Safa Ghalib Dekan

Student Name: Rayaheen / 5th stage student

❖ Management of severely resorbed mandibular ridge

Insufficient supporting structures diminish support and allow surrounding mobile tissues to encroach upon the denture borders. Therefore, the primary goal of the impression procedure is to achieve maximum coverage.

In this case, the patient was treated with an upper complete denture and a lower semi-complete denture using the double tray impression technique (Sandwich technique) for the lower arch. The facial contour was effectively restored, resulting in high patient satisfaction.

Students Cases under Teacher's Supervision

Supervised By: Asst. Prof. Dr. Faaz Yaqoob

Training course

- Starting the implant training module in the oral surgery clinic

Students Cases under Teacher's Supervision

Supervised By: Asst. Lec. Nagham Hussein Ali

Training course

❖ Clinical training on the princples of Flap reflection and suturing techniques For the 4th grade dental students as apart of the clinical requirments at the oral surgery clinic.

Students Cases under Teacher's Supervision

Supervised By: Asst. Prof. Dr. Faaz Yaqoob

- Drainage of labial abscess

A young female attended the oral surgery clinic at the College of Dentistry with a gum boil on the labial sulcus against a crowned upper central incisor with a duration of a couple of days. The crown was done a couple of months ago. The patient has been feeling heaviness in the tooth since then. Clinically, the tooth was tender to percussion, and the swelling was fluctuant.

An incision was performed after administering infiltration anesthesia around the swelling. The incision was made using a #15 blade at a non-dependent area to minimize discomfort. Pus immediately exuded from the incision. After completing the incision, drainage was done with Hilton's method using tweezers. No suturing was required to allow for drainage. Metronidazole 200 mg tablets were prescribed for the patient.

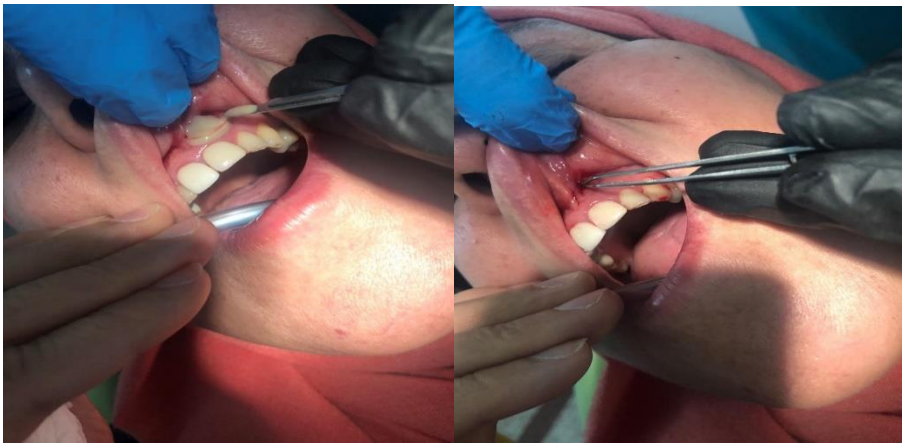

Students Cases under Teacher's Supervision

Supervised by: Asst. Prof. Dr. Raya Rasheed
Asst. Prof. Yamama Adnan

Student Name: Rusul Sabah Badr

❖ Cases treated at Prevention Clinic

In the following pictures a class IV fractures cases on anterior teeth are restored with composite using a minimally invasive approach that allows for more tissue preservation while achieving optimal aesthetic functional outcomes.

Student name: Haneen Hussain Makkie

Students Cases under Teacher's Supervision

Student Name: Tiba Ali Abdulameer

Student Name: Shukran mohammed

Student Name: Nabaa Abass jasim

Student Name: Ruqia Ammar Hashim

Students Cases under Teacher's Supervision

- Here the case is class v which is very common in primary canine.

Student Name: Zainab Ahmed Hassan

Students Cases under Teacher's Supervision

Supervised By: Asst. Prof. Dr. Wajnaa Fareed Qasim
Student Name: Abdulrahman Fadil Sabeeh

- A thirty-year-old heavy smoker male with generalized smoker melanosis concomitant with smoker's keratosis extending on keratinized oral mucosa and lower lip.

Students Cases under Teacher's Supervision

Supervised by: Lec. Noor Hashim Mohammad
Student name: Ruaa Oday Farouk

❖ A thirty-seven-year-old male with a history of long-term smoking, resulting in brown hairy tongue.

Students Cases under Teacher's Supervision

Supervised by: Asst. Lec. Shahad Abbas Azeez
Students Names: Shams Aydin Nourelddin/ Sura Qutaiba Hameed

Morsicatio Mucosae Oris is a common condition with a fancy name. "Morsicatio" is derived from the Latin word "morsus," which means "bite". The condition is caused by chronic mucosal chewing and is frequently observed in people under stress or those exhibiting psychological conditions.

- **Case 1 :** A 23-year-old female college student attended the oral medicine clinic, complaining of asymptomatic bilateral white lesions on the buccal mucosa that had been present for one and a half years. Otherwise, the patient was healthy, and her medical history was unremarkable.

- During the intra-oral examination, asymmetrical bilateral white lesions with a shredded surface were observed on the anterior buccal mucosa along the occlusal plane. The patient confirmed a history of a chronic cheek-biting habit, which worsened during exams. A diagnosis of morsicatio mucosae oris was established.

- **Case 2**

A 26-year-old male patient visited the periodontal clinic for scaling and polishing. The patient was in good health with no significant medical history. During the intraoral examination, asymmetrical bilateral white areas with irregular ragged surfaces were observed on the buccal mucosa, accompanied by erosion on the right side. The lesions were asymptomatic, and the patient was unaware of them. The patient reported a history of bruxism and a habit of cheek-biting when feeling angry. A diagnosis of morsicatio mucosae oris was established.

Students Cases under Teacher's Supervision

Supervised By: Asst. Lec. Mais M. Almaeeni
Student Name: Ali R. Ibrahim

❖ Pedodontic clinic

- Partial denture insertion for a 12-year-old child patient who lost his upper right central incisor due to trauma.

- Space maintainer (band & loop) insertion for a 7-year-old patient after extraction of her upper left primary first molar due to its destruction by dental caries.

Students Cases under Teacher's Supervision

- Stainless steel crown adaptation and insertion for a 5-year-old child. The lower right primary first molar was treated with pulpectomy and glass ionomer filling as the final restoration, followed by the adapted crown. Cemented with glass ionomer luting cement.

- Stainless steel crown adaptation and insertion for a 6-year-old child. The lower right primary first molar was treated with pulpotomy and glass ionomer filling as the final restoration, then the adapted crown was cemented with glass ionomer luting cement.

- Pulpotomy treatment and glass ionomer filling for the lower right primary second molar for a 9-year-old child."

Students Cases under Teacher's Supervision

Supervised By: Asst. Lec. Shahad Zahid
Student Name: Fatima Nabil shineshal/ 5th Stage

❖ **Case 1:**

- Patient female 8 years old suffering from severe pain in lower left deciduous first molar with deep caries. She has class III malocclusion with long face. We do Pulp therapy and then doing Stainless steel crown for this tooth.

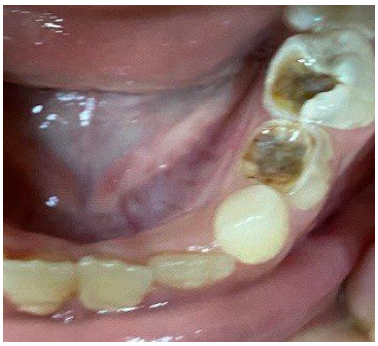

❖ **Case 2:**

- Patient female 9 years old suffering from deep caries in lower deciduous second molars in both sides (right and left). We do extraction for those teeth and then construct passive lingual arch space maintainer.

Zomorod Tariq sofar (B.D.S)

Students Cases under Teacher's Supervision

Supervise by: Asst. Lec. Abeer Ahmed Yahya (Pedodontist)
Asst. Lec. Sarah Abdulameer Alsharefy (Conservative dentistry)
Assisted by: Ahmed Riyadh (B.D.S)
Zumorood Tareq (B.D.S)
Haneen Hussain Alrawi (Student)

❖ Modified treatment of Coronal third fractures of the root (cervical fracture)

"A 14-year-old boy presented to the pediatric dental clinic, with a cervical fracture (see Figure 1) persisting for more than 3 years, with the crown remaining attached to the root palatably. Traditional treatment options exclude crown fabrication due to the patient's age, So, we decided to perform labial fixation (see Figure 2), access opening, and endodontic treatment (see Figure 3), followed by removal of the labial fixation and reuniting the crown and root using (etching, bonding, flowable composite), and applying a thin composite layer in the fracture line (see Figure 4). To enhance the fracture resistance of the crown, we placed a fiber post and adjusted the crown out of occlusion (see Figure 5)."

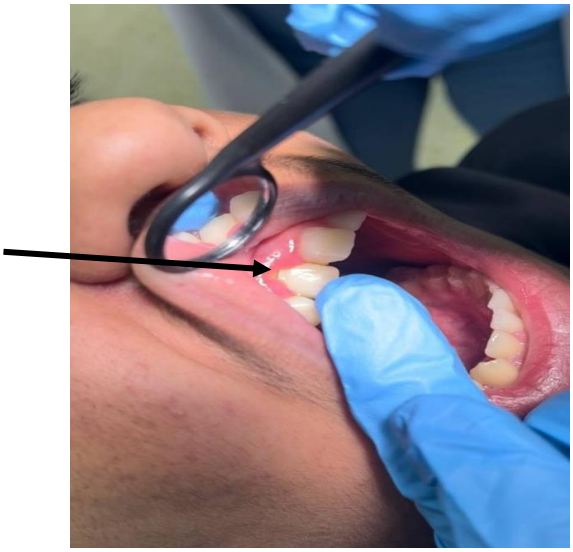

Figure (1)

Figure (2)

Students Cases under Teacher's Supervision

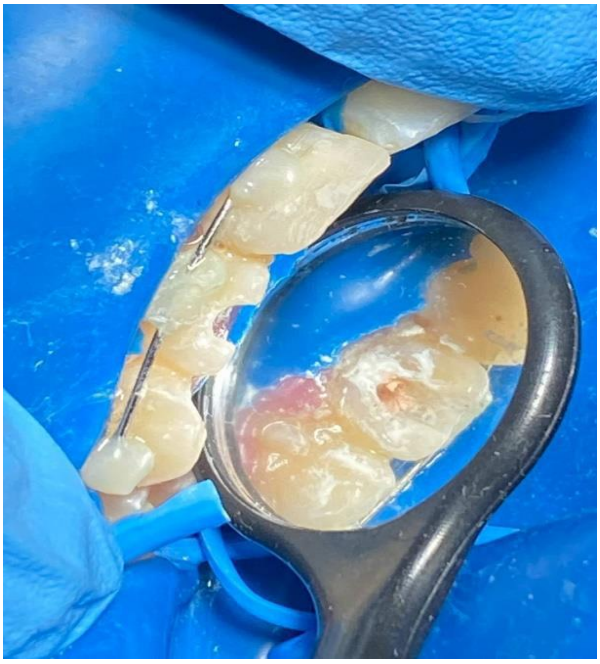

Figure (3)

Figure (4)

Figure (5)

Students Cases under Teacher's Supervision

Supervised By: Lec. Dr. Samer Salim Othman
Student Name: Naba'a Mustafa Kadhum/ 5th stage

- A 13-year-old female patient with a midline diastema was treated in the orthodontic clinic of Ibn Sina University of Medical and Pharmaceutical Sciences with a removable appliance featuring the following design: Adam clasps on the upper first molars, closing finger springs, and a Hawley labial arch.



Before **During** **After**

- A 10-year-old female patient with anterior crossbite was treated in the orthodontic clinic of Ibn Sina University of Medical and Pharmaceutical Sciences with a removable appliance featuring the following design: Adam clasps on the upper first molars, a posterior bite plate, a recurved Z spring, and a Hawley labial arch. The treatment was administered by fifth-grade student Ronak Al-Baha, under the supervision of lecturer Dr. Samer Salim Othman.



Before **During** **After**

Students Cases under Teacher's Supervision

Supervised by: Assist. Lec. Sarah AL-sharefy
Student name: Mohamed Wissam
Management of cervical caries lesion / operative teaching clinic

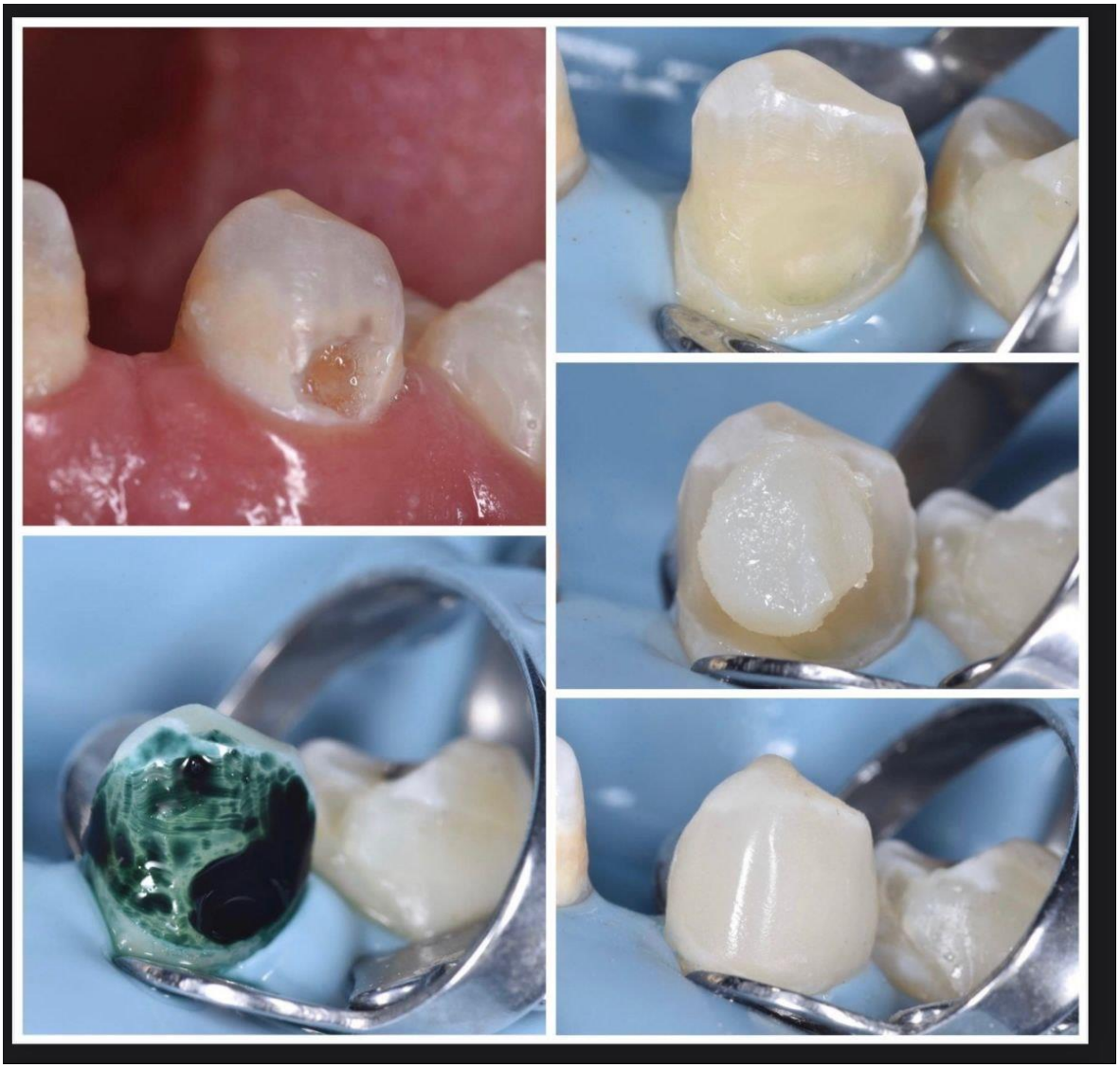

Students Cases under Teacher's Supervision

Supervised by: Asst. Lec. Mohamed Qassim.
Student name: Mohamed Wissam
Management of class I caries lesion / operative teaching clinic